

# Postural tachycardia syndrome following human papillomavirus vaccination

S. Blitshteyn

Department of Neurology, State University of New York at Buffalo School of Medicine and Biomedical Sciences, Buffalo, NY, USA

## Keywords:

disorders of the autonomic nervous system, human papillomavirus vaccination, neuropathy, postural tachycardia syndrome, small fibers, vaccination

**Background and purpose:** Postural tachycardia syndrome (POTS) is a heterogeneous disorder of the autonomic nervous system that may have an autoimmune etiology.

**Methods:** Six patients who developed new onset POTS 6 days to 2 months following human papillomavirus vaccination are reported.

**Results:** Three patients also had neurocardiogenic syncope, and three patients were diagnosed with possible small fiber neuropathy. Symptoms in all patients improved over 3 years with pharmacotherapy and non-pharmacological measures but residual symptoms persisted. Molecular mimicry with formation of cross-reacting autoantibodies to the potential targets of the autonomic ganglia, neurons, cardiac proteins or vascular receptors is considered as a possible pathogenesis of new onset POTS after immunization.

**Conclusion:** Correct diagnosis of POTS and awareness that POTS may occur after vaccination in young women is essential for prompt and effective management of this condition.

Received 10 July 2013

Accepted 23 August 2013

## Introduction

Human papillomavirus (HPV) vaccine, Gardasil, has been approved for prevention of cervical cancer in young women. Postural tachycardia syndrome (POTS), a disorder of the autonomic nervous system, has been previously reported in one patient following vaccination with Gardasil [1]. In this study, an additional five cases of new onset POTS after vaccination with Gardasil are described.

## Methods

In this case series, medical records from six patients were reviewed. The case history of patient 1 was reported previously [1].

## Results

See Table 1 for a summary of the findings.

### Patient 1

A 20-year-old athletic female with no pre-existing medical history developed weight loss, dizziness, fati-

gue, nausea, tachycardia and exercise intolerance 2 weeks after receiving the first out of the three-series vaccination with HPV vaccine, Gardasil [1]. After thorough diagnostic investigations excluded possible cardiac, endocrine, infectious, rheumatological and psychiatric causes, a tilt table test was done. The tilt table test demonstrated an increase in heart rate from 72 bpm supine to 140 bpm within 10 min of tilt without any changes in blood pressure, consistent with the diagnostic criteria for POTS [2]. With the use of pharmacotherapy consisting of pyridostigmine for postural tachycardia and orthostatic intolerance and bupropion and modafinil for fatigue and daytime somnolence, as well as non-pharmacological management with increased salt and fluid consumption, the patient's symptoms of orthostatic intolerance and gastrointestinal disturbance have gradually improved over the course of 15 months. The patient was able to return to school full-time but continued to experience some functional limitations and was unable to resume her previous athletic activities.

### Patient 2

A 22-year-old previously healthy female experienced a sudden onset of diarrhea, nausea and weight loss approximately 2 months after receiving the third HPV vaccine. A thorough gastrointestinal diagnostic

Correspondence: S. Blitshteyn, Department of Neurology, State University of New York at Buffalo School of Medicine and Biomedical Sciences, 100 High Street, Buffalo, NY 14203, USA (tel.: +1 716 531 4598; fax: +1 716 478 6917; e-mail: sb25@buffalo.edu).

**Table 1** POTS after HPV vaccine: patient characteristics, investigations, treatment and outcome

Patient	Age (years)	Onset after HPV vaccine dose	Symptoms	Diagnostic tests	Treatment	Outcome
1	20	2 weeks after 1st dose	Weight loss, dizziness, fatigue, exercise intolerance	TTT: POTS	Bupropion, pyridostigmine, modafinil	Improved over 15 months
2	22	2 months after 3rd dose	Diarrhea, weight loss, fatigue, dizziness, syncope	TTT: POTS, NCS; QSART: possible SFN	Midodrine, fludrocortisone	Improved over 2 years
3	12	5 days after 2nd dose; worsening 3 weeks after 3rd dose	Syncope, pre-syncope, dizziness, SOB	Holter monitor: episodic sinus tachycardia; clinical diagnosis of POTS, NCS	Fludrocortisone	Improved over 3 years
4	15	4 weeks after 1st dose	Dizziness, headache, pre-syncope, syncope	TTT: POTS, NCS	Sertraline	Improved over 2 years
5	14	5 days after 1st dose	Paresthesia, tachycardia, fatigue, headache, diarrhea, weight loss	TTT: POTS, NCS; QSART: possible SFN; ANA 1:160	Metoprolol, amitriptyline	Improved over 2 years
6	18	3 weeks after 1st dose; worsening 3 months after 2nd dose	Paresthesia, leg pain, orthostatic intolerance, fatigue, dizziness	Clinical diagnosis of POTS and possible SFN; ANA 1:320	Duloxetine, doxepin	Improved over 3 years

POTS, postural tachycardia syndrome; HPV, quadrivalent human papillomavirus vaccine – Gardasil (Merck); TTT, tilt table test; NCS, neurocardiogenic syncope; QSART, quantitative sudomotor axon reflex screen; SFN, small fiber neuropathy; SOB, shortness of breath; ANA, antinuclear antibodies.

workup failed to reveal any underlying etiology, and the patient was diagnosed with irritable bowel syndrome. In addition to persistent gastrointestinal symptoms, the patient also developed lightheadedness, dizziness, pre-syncope and episodic tachycardia. A tilt table test revealed a rise in heart rate from 90 bpm supine to 134 bpm standing, within 1 min of tilt. At the twentieth minute of tilt, the patient experienced a drop in blood pressure to 88/43 accompanied by symptoms of pre-syncope. The tilt table test was consistent with POTS and neurocardiogenic syncope (NCS). Further autonomic testing revealed normal heart rate variability and Valsalva response, and quantitative sudomotor test showed mild reduction in the distal leg suggestive of a small fiber neuropathy. In addition to an increased fluid/salt intake, the patient was treated with midodrine for vasoconstriction and fludrocortisone for volume expansion, and her symptoms have gradually improved over the course of 2 years.

### Patient 3

Six days after receiving a second dose of the HPV vaccine, a 12-year-old previously healthy female began experiencing episodic loss of consciousness, which after neurological and cardiac evaluation was determined to be secondary to NCS. Holter monitor demonstrated a heart rate range from 44 bpm to 212 bpm with the patient reporting shortness of breath and palpitations at the time of sinus tachycardia occurring

with exertion. Orthostatic blood pressure and heart rate assessment demonstrated a supine heart rate of 65 bpm and a maximum heart rate of 122 bpm without orthostatic hypotension during a 5 min standing test, which was consistent with POTS; a tilt table test was not obtained. The patient's symptoms improved significantly with the use of fludrocortisone and high sodium diet for volume expansion, and she was able to attend school full-time and play sports. Subsequently, she received a third dose of HPV vaccine, and 3 weeks after vaccination her symptoms of dizziness and episodes of loss of consciousness intensified. After a second MRI of the brain and 24-h video EEG at the epilepsy monitoring unit revealed no abnormalities, the etiology of the episodes was determined to be once again secondary to NCS. The course of her symptoms over the following 12 months after the third Gardasil vaccine appeared to be relapsing and remitting, with several syncope-free months followed by recurrence of syncope. Three years after the onset of syncope, the patient's daily symptoms have mostly resolved, and she experiences syncope only occasionally.

### Patient 4

A healthy 15-year-old female developed new onset dizziness and headache 4 weeks after receiving the first injection with HPV vaccine. In the following 2 months she began to experience syncope and pre-syncope, along with dizziness, shaking, muscle twitch-

ing, hyperventilation and generalized weakness. MRI of the brain and magnetic resonance angiography of the head and neck, as well as the EEG, were unremarkable. A tilt table test demonstrated an increase in heart rate from 75 bpm supine to 112 bpm within 1 min of tilt without orthostatic hypotension. After 7 min of tilt, the heart rate decreased to 60 bpm with an unobtainable blood pressure, at which time the patient became unresponsive. She regained consciousness and her vital signs stabilized on assuming a supine position. The tilt table test was consistent with POTS and NCS. With pharmacotherapy consisting of a selective serotonin reuptake inhibitor (sertraline), which can be helpful in patients with POTS and NCS, her symptoms improved but persisted over the following 2 years. She was able to attend school 4 h per day with pre-syncope occurring between one and four times per month.

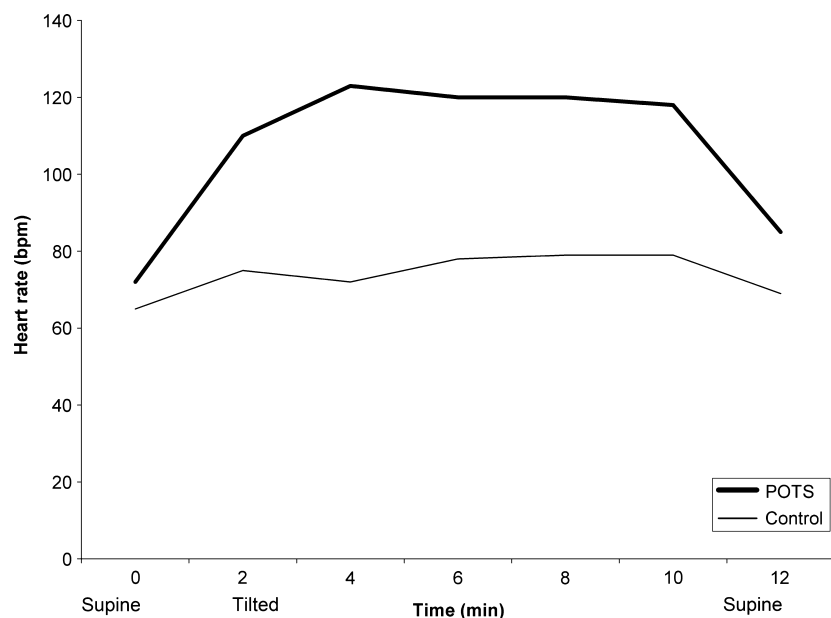
#### Patient 5

Five days after receiving the first injection of HPV vaccine, a previously healthy 14-year-old female experienced numbness and tingling in the toes. Over the following 2 weeks, the numbness and tingling increased to involve the lower extremities and pelvis. Other symptoms, such as fatigue, headache, nausea, diarrhea, weight loss and tachycardia, ensued. MRI of the brain and cervical spine were unremarkable, and laboratory testing showed positive antinuclear antibodies (ANA) with titers 1:160 with speckled pattern. Rheumatological evaluation was unrevealing raising a possibility of fibromyalgia. A tilt table test demon-

strated a supine heart rate of 72 bpm which increased to a maximum of 123 bpm within 10 min of tilt without evidence of orthostatic hypotension (Fig. 1). Heart rate responses to the Valsalva maneuver and deep breathing test were unremarkable, and sweat output in the leg with the quantitative sudomotor test was borderline reduced. The results of the autonomic testing indicated POTS and possible small fiber neuropathy, and the patient was started on metoprolol tartrate to control the tachycardia. Over the following 2 years, her symptoms had improved with the use of metoprolol tartrate for POTS and amitriptyline for headache prophylaxis.

#### Patient 6

An 18-year-old healthy female experienced numbness and tingling in the right arm 3 weeks after receiving the first Gardasil vaccine injection into the right deltoid muscle. Over the following 3 months, she developed lower back pain, neck stiffness and pain in the legs resulting in difficulty sitting in class. Diagnostic tests obtained at that time included an unremarkable MRI of the cervical and lumbar spine and elevated ANA titers of 1:320 with speckled and homogeneous pattern. Despite the symptoms experienced after the first injection, she received a second Gardasil vaccine 3 months after the first injection, which resulted in significant exacerbation of previous symptoms. Additional symptoms, such as fatigue, orthostatic intolerance, dizziness, urinary incontinence and blurry vision appeared, which in conjunction with pain and numbness resulted in significant functional impairment. In



**Figure 1** A tilt table test demonstrating an immediate 51 bpm heart rate increase from 72 bpm supine to 123 bpm tilted in this POTS patient (patient 5). In contrast, heart rate increases only by <20 bpm in a healthy subject (control). Blood pressure (not shown) remained stable in both the POTS patient and control.

fact, the patient became wheelchair-bound at that point and had to take medical leave from college for a full semester. Bedside heart rate assessment revealed a supine heart rate of 88 bpm and a maximum heart rate of 128 bpm within 5 min of standing. Neurological examination demonstrated reduced temperature sensation in the hands and feet without motor weakness. MRI of the brain, cervical, thoracic and lumbar spine, electromyography and cerebrospinal fluid analysis were unrevealing. Serological tests were only remarkable for elevated ANA titers. Based on clinical presentation, the patient was diagnosed with POTS and possible small fiber neuropathy; a tilt table test and further autonomic reflex screen testing were not performed. Over the following 3 years, the patient's symptoms improved significantly with the use of duloxetine and doxepin for neuropathic pain, and she was able to return to college full-time.

## Discussion

POTS is a heterogeneous disorder of the autonomic nervous system characterized by orthostatic tachycardia, other symptoms of orthostatic intolerance, and non-orthostatic symptoms such as fatigue, gastrointestinal disturbance and migraine headache [3]. POTS primarily affects women of reproductive age with a female-to-male ratio of 5:1 and can commonly be triggered by a virus, surgery, pregnancy or trauma [2]. POTS following vaccination has been previously described in one patient, who was also included in this case series as patient 1 [1]. Other related conditions, such as small fiber neuropathy, autonomic neuropathy, complex regional pain syndrome and fibromyalgia have been reported after immunization with various vaccines, including Gardasil [4–7].

Although POTS is a syndrome that may arise from various mechanisms and etiologies, there has been significant evidence in recent years that POTS may be an autoimmune disorder. Several autoantibodies have been identified in patients with POTS, including ganglionic N-type acetylcholine receptor antibody [3], antibodies to various cardiac proteins [8] and antibodies to  $\beta 1/2$ -adrenergic and M2/3 muscarinic receptors [9]. Based on these findings, POTS is considered as an attenuated form of autoimmune autonomic neuropathy in a subset of patients [7].

Possible pathogenesis of the new onset POTS after vaccination may include the mechanism of molecular mimicry, whereas HPV vaccine epitopes may induce formation of cross-reacting antibodies against potential targets of the autonomic ganglia, neurons, cardiac proteins or  $\beta 1/2$ -adrenergic and M2/3 muscarinic receptors. Additionally, induction of bystander lym-

phocyte activation and a broad spectrum of cytokine responses elicited by the HPV vaccine may also be involved [10].

In the case series described here, all six previously healthy young women developed symptoms of POTS within 6 days to 2 months after immunization with Gardasil vaccine. The time frame of symptom onset is consistent with that of other well-known post-vaccination syndromes, such as Guillainé–Barre syndrome and acute disseminated encephalomyelitis. Furthermore, two patients experienced significant symptomatic exacerbation following a re-challenge with a subsequent Gardasil injection, a phenomenon that suggests a more robust autoimmune response yielding more severe symptoms with each subsequent exposure to the HPV vaccine. Additionally, two patients exhibited elevated ANA titers after vaccination with Gardasil, which may be another indicator of an autoimmune process induced by immunization, although it may also be a non-specific finding.

All patients in the case series were diagnosed with POTS based on the accepted diagnostic criteria, which include clinical manifestations and objective evidence of a greater than 30 bpm heart rate increase from supine to standing position within 10 min of standing or a tilt table test [2,11]. Four of six patients had a tilt table test confirmation of POTS, and two patients had complete autonomic function tests, which were remarkable only for mild abnormalities in the quantitative sudomotor test. Three patients had NCS in addition to the diagnosis of POTS, and three patients also had a diagnosis of possible small fiber neuropathy based on clinical features and an abnormal quantitative sudomotor test. Interestingly, the course of POTS following vaccination with Gardasil was similar in all six patients, with all patients improving in a 2–3 years' time frame with the use of standard pharmacotherapy for POTS, migraine headaches and neuropathic pain and non-pharmacological measures for POTS, such as liberal fluid and salt consumption. Nevertheless, none of the patients experienced complete resolution of symptoms, and all patients continued to experience some residual symptoms.

None of the women in the case series had a pre-existing personal or family history of POTS, syncope or other neurological or autoimmune disorders, excluding a possibility of secondary or genetic causes of POTS. The temporal association between vaccination with Gardasil and the onset of symptoms of POTS in healthy young women is significant and deserves further investigation for assessment of a possible causal relationship.

Although syncope immediately following the injection is noted as the most common adverse effect of

Gardasil vaccine, with a reported rate of 8.2 events per 100 000 doses distributed [12], the rate of chronic recurrent NCS or the rate of other autonomic disorders such as POTS is unknown. The lack of data is probably secondary to failure to properly diagnose POTS and other autonomic disorders or misdiagnosis with anxiety, panic or eating disorders or other disorders of altered consciousness or awareness, all of which lead to under-reporting and a paucity of data on the incidence of the autonomic disorders after vaccination.

### Conclusion

In summary, POTS may occur following vaccination with HPV vaccine, Gardasil. Given an increased prevalence of POTS in young women and an indication for vaccination with Gardasil in the same patient population, physicians should be aware of a possible association between vaccination with Gardasil and new onset POTS. Further studies are necessary to investigate whether there is a causal relationship.

### Acknowledgement

None.

### Disclosure of conflicts of interest

The author declares no financial or other conflicts of interest.

### References

1. Blitshteyn S. Postural tachycardia syndrome after vaccination with Gardasil. *Eur J Neurol* 2010; **17**: e52.
2. Low PA, Opfer-Gehrking TL, Textor SC, et al. Postural tachycardia syndrome (POTS). *Neurology* 1995; **45**: S19–S25.
3. Thieben MJ, Sandroni P, Sletten DM, et al. Postural orthostatic tachycardia syndrome: the Mayo Clinic experience. *Mayo Clin Proc* 2007; **82**: 308–313.
4. Souayah N, Ajroud-Driss S, Sander HW, et al. Small fiber neuropathy following vaccination for rabies, varicella and Lyme disease. *Vaccine* 2009; **27**: 7322–7325.
5. Richards S, Chalkiadis S, Lakshman R, et al. Complex regional pain syndrome following immunization. *Arch Dis Child* 2012; **97**: 913–915.
6. Ablin JN, Shoenfeld Y, Buskila D. Fibromyalgia, infection and vaccination: two more parts of the etiologic puzzle. *J Autoimmun* 2006; **27**: 145–152.
7. Vernino S, Sandroni P, Singer W, Low PA. Invited Article: Autonomic ganglia: target and novel therapeutic tool. *Neurology* 2008; **70**: 1926–1932.
8. Wang XL, Chai Q, Charlesworth MC, et al. Autoimmune-reactive IGGs from patients with postural tachycardia syndrome. *Proteomics Clin Appl* 2012; **6**: 1–11.
9. Yu X, Stavrakis S, Hill MA, et al. Autoantibody activation to beta-adrenergic and muscarinic receptors contributes to 'autoimmune' orthostatic hypotension. *J Am Soc Hypertens* 2012; **6**: 40–47.
10. Pinto LA, Castle PE, Roden RB, et al. HPV 16 L1 VLP vaccine elicits a broad-spectrum of cytokine responses in whole blood. *Vaccine* 2005; **23**: 3555–3564.
11. Raj SR. Postural tachycardia syndrome (POTS). *Circulation* 2013; **127**: 2336–2342.
12. Slade BA, Leidel L, Vellozzi C, et al. Postlicensure safety surveillance for quadrivalent human papillomavirus recombinant vaccine. *JAMA* 2009; **302**: 750–757.